

The dot-in-circle sign of mycetoma on MRI

Jyoti Kumar, Atin Kumar, Pradeep Sethy, Somesh Gupta

ABSTRACT

Mycetoma is a chronic granulomatous disease prevalent in tropical countries, but it also occurs in Europe and the United States. Early diagnosis is important as it has therapeutic implications. Although biopsy and microbiological culture provide the definitive diagnosis, these are difficult to achieve in many instances. The dot-in-circle sign is a recently proposed magnetic resonance imaging (MRI) sign of mycetoma, which is likely to be highly specific. We present a case of mycetoma of the thigh with characteristic MRI features. To the best of our knowledge, only 2 cases of mycetoma of the foot demonstrating this sign have been previously published.

Key words: • *maduromycosis* • *magnetic resonance imaging*

Mycetoma is a debilitating chronic granulomatous disease prevalent in tropical and subtropical regions, but it also occurs in Europe and the United States. It was first described in Madura, India, in 1846; hence, the eponym Madura foot (1). The disease can be caused by 2 groups of organisms, the Eumyces, or true fungi (eumycetoma), and the Actinomyces, which are filamentous bacteria of the order Actinomycetales (actinomycetoma) (1). The evolution of the disease is slow and mostly painless. Patients present many years after the onset of infection, often with extensive soft tissue and bone involvement (2). The organism first lodges in the soft tissues. Bones are almost always attacked from outside, in contrast to bacterial osteomyelitis, and periosteal reaction and cortical erosion may then be seen. Early diagnosis, before the appearance of sinuses and grains, is difficult. If left untreated, it may result in severe disability, often necessitating amputation. Although biopsy or microbiological culture of the discharge will yield the definitive diagnosis, both may be difficult to achieve with fastidious organisms. Imaging can aid in the early diagnosis of the disease. We present the magnetic resonance imaging (MRI) characteristics of a patient with mycetoma that demonstrated the recently described dot-in-circle sign, suggesting the possible diagnosis before the histological diagnosis.

Case report

A 28-year-old man complained of a mass in the right thigh for 4 years. He previously underwent a wide excision biopsy with skin grafting in another institution, based on the clinical suspicion of a soft tissue tumor. Histopathological evaluation revealed it to be an inflammatory process with chronic abscess formation. The patient was treated with multiple courses of oral and intravenous antibiotics over the following 6–8 months, to which he did not respond. During this period the patient developed multiple discharging sinuses with which he presented to our hospital. On physical examination (Fig. 1), non-tender swelling involving mainly the posteromedial aspect of the right thigh was noted. It was associated with numerous chronic sinuses. No grains, however, were seen from any of the discharging sinuses. General examination was unremarkable, with no other soft tissue masses. Blood and serum chemistry were also unremarkable.

Plain radiograph of the right thigh showed soft tissue swelling with superficial skin ulceration. No calcification or bone destruction was seen.

MRI was performed to characterize and evaluate the extent of the disease. T2-weighted and T2-weighted fat-saturated MRI revealed diffuse hyperintensity involving subcutaneous tissue, muscles, and intermuscular fascial planes, with multiple focal fluid collections and overlying skin ulceration. In addition, multiple small discrete spherical hyperintense lesions were noted, which were divided by a network of low-intensity soft

From the Departments of Radiology (J.K., A.K. ✉ atinkumar@rediffmail.com), and Dermatology (P.S., S.G.), All India Institute of Medical Sciences, New Delhi, India.

Received 5 August 2006; revision requested 8 October 2006; revision received 9 October 2006; accepted 9 October 2006.

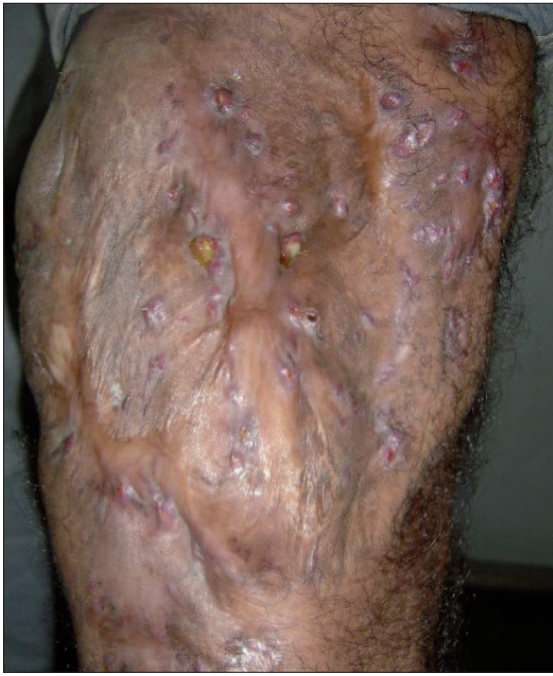

Figure 1. Photograph of the posterior right thigh shows soft tissue thickening with multiple sinuses.

tissue. In the center of some of these lesions, there was a tiny hypointense focus, resulting in the dot-in-circle sign (Figs. 2, 3). Small conglomerated low-intensity foci and microabscesses were also seen at other sites (Figs. 4, 5). The underlying bones were normal. The diagnosis of mycetoma was made based on these findings.

Subsequently, a biopsy was performed, which revealed granulomatous inflammation. There were multiple neutrophilic microabscesses surrounded by granulation tissue composed of acute and chronic inflammatory cells. There was dense connective tissue, containing plasma cells, macrophages, lymphocytes, eosinophils, and occasional giant cells, separating the foci of inflammation. Although fungal organisms could not be isolated, the histopathological features were consistent with mycetoma.

The patient was put on itraconazole therapy and significant clinical improvement was observed at the 11th month follow-up.

Discussion

The term mycetoma is a clinical entity, which applies to a chronic inflammatory process of soft tissue, usually of the foot, resulting from the implantation of one or various fungi or actinomycetes. Initially there is the

formation of soft tissue swelling with induration due to the underlying granulation tissue. It usually progresses to the formation of sinuses and extrusion of grains. The lesion may be confined to the soft tissue for years before bone involvement occurs. The diagnosis of mycetoma should not be considered by physicians when presentation is limited to soft tissues, without sinus or bone involvement. Although mainly a disease of the tropics, patients living in temperate regions may also be affected by this entity (3, 4), though they are often misdiagnosed as soft tissue tumors in the early stage.

Histopathologically, the inflammatory reaction of mycetoma is non-specific and, in the absence of isolation of fungal grains, it is difficult to differentiate from other inflammatory soft tissue processes and cold abscesses, which is not an uncommon occurrence.

Although various radiographic bone changes have been described in cases of mycetoma, bone involvement occurs late in the course of the disease, when non-surgical cure is unlikely. Non-invasive imaging with MRI can characterize the soft tissue masses of mycetoma and aid in early diagnosis.

Czechowski et al. (5) described the MR appearance of mycetomas and found small low-signal intensity lesions on T1-weighted and T2-weighted MR im-

ages in 16 of 20 patients. They suggested that these appearances were due to susceptibility from the metabolic products within the grains. They observed lesions showing a conglomerate of low-intensity foci, as was seen in the presented case.

The dot-in-circle sign is a recently described sign reflecting the unique pathological feature of mycetoma. It is seen as a tiny hypointense focus within high-intensity spherical lesions. This sign was proposed by Sarris et al. (6) in 2003 on T2-weighted, STIR, and T1-weighted fat-saturated gadolinium-enhanced images. They correlated the MRI and histological findings in 2 cases of mycetoma and concluded that the small central hypointense foci represented the fungal balls or grains, while the surrounding high-signal intensity foci represented the inflammatory granulomata (6). The low-intensity tissue seen surrounding these lesions represented the fibrous matrix. They proposed that it is likely to be a highly specific sign for mycetoma (6). We were able to demonstrate similar MRI findings in the presented case. Although the histopathological specimen in our case showed features of chronic granulomatous inflammatory response consistent with the clinical and imaging diagnosis of mycetoma, fungal grains were not visualized. We postulate that the grains may not have been present in the biopsy specimen, which represents only a small portion of the extensively involved area. MRI clearly depicted the conglomerated hypointense foci scattered in a few regions, which likely represent the susceptibility effect due to the grains. The marked clinical response to itraconazole therapy also substantiated the diagnosis in our case.

Few radiographic bone changes have been described to distinguish between actinomycetoma and eumycetoma (1). Eumycotic lesions tend to form a few cavities in bone ≥ 1 cm in diameter, while actinomycetes often form smaller, but more numerous cavities. In a study by Lewall et al. (1), a moth-eaten appearance caused by a combination of irregular periosteal reaction, periosteal erosion, and small cavities within bone were seen in 25% of cases of actinomycetoma, but in none of the patients with eumycetoma. The distinction between the 2 forms of soft tissue mycetoma was not possible with MRI.

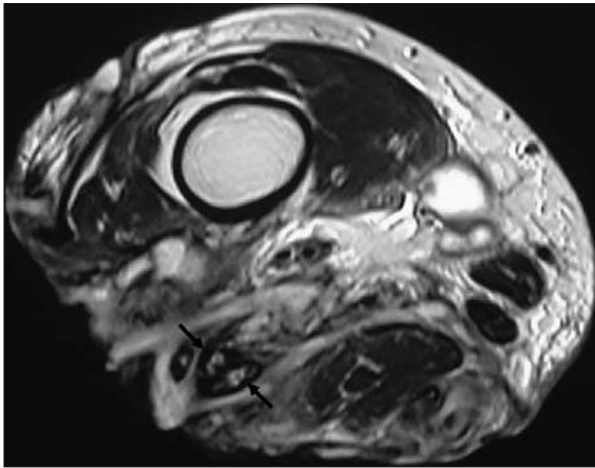


Figure 2. T2-weighted transverse MR image of the right thigh reveals extensive inflammatory changes. Multiple small spherical hyperintense lesions separated by tissue of low signal intensity are noted. Some of these lesions (*arrows*) show a central tiny hypointense focus, resulting in the dot-in-circle sign.

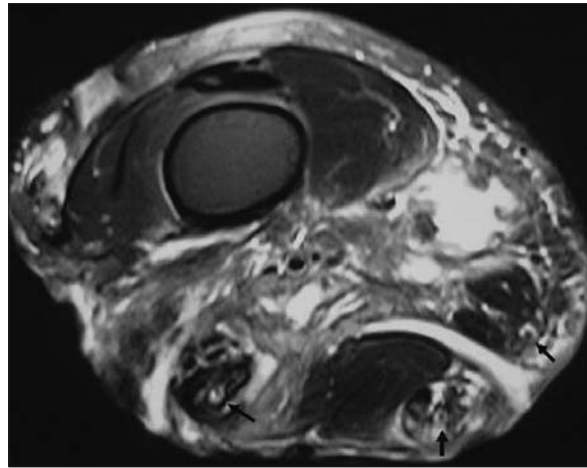


Figure 3. T2-weighted fat-saturated transverse MR image of the right thigh shows inflammatory soft tissue changes with fluid collections. At least 3 spherical hyperintense lesions, each with a tiny central hypointense focus, can be seen (*arrows*).

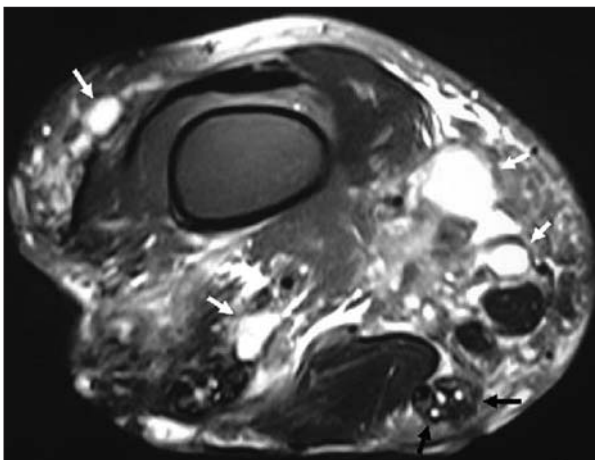


Figure 4. T2-weighted fat-saturated transverse MR image of the right thigh shows multiple microabscesses separated by a low-intensity matrix seen posteriorly (*black arrows*), distinct from the adjacent musculature. Note the presence of marked inflammatory changes with multiple fluid collections (*white arrows*).

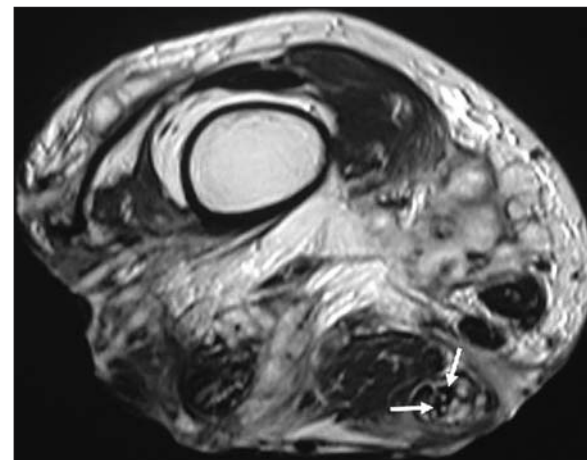


Figure 5. T2-weighted transverse MR image of the right thigh shows multiple small adjoining low-intensity lesions (*arrows*) that may represent a conglomerate of grains in the background of diffuse hyperintense inflammatory changes.

To conclude, we stress the importance of MRI in the early diagnosis of mycetoma, even before the development of sinuses and/or extrusion of grains. Furthermore, as these fastidious organisms may be difficult to demonstrate either on biopsy or microbiological culture, the clinical picture often necessitates multiple surgical biopsies, thus exacerbating morbidity due to delays in diagnosis and therapeutic intervention. MRI can be useful in such situations. It can strongly suggest the diagnosis of mycetoma when it demonstrates the

dot-in-circle sign, conglomerated low-signal intensity foci, or microabscesses in the background of a hypointense matrix as described above.

References

1. Lewall DB, Ofole S, Bendl B. Mycetoma. *Skeletal Radiol* 1985; 14:257–262.
2. Abd El, Bagi ME. New radiographic classification of bone involvement in pedal mycetoma. *AJR Am J Roentgenol* 2003; 180:665–668.
3. Salamon ML, Lee JH, Pinney SJ. Madura foot (madurella mycetoma) presenting as a plantar fibroma: a case report. *Foot Ankle Int* 2006; 27:212–215.
4. Ispoglou SS, Zorpala A, Androulaki A, Sipsas NV. Madura foot due to *Actinomyces madurae*: imaging appearance. *Clin Imaging* 2003; 27:233–235.
5. Czechowski J, Nork M, Haas D, Lestringant G, Ekelund L. MR and other imaging methods in the investigation of mycetomas. *Acta Radiologica* 2001; 42:24–26.
6. Sarris I, Berendt AR, Athansous N, Ostlere SJ. MRI of mycetoma of the foot: two cases demonstrating the dot-in-circle sign. *Skeletal Radiol* 2003; 32:179–183.